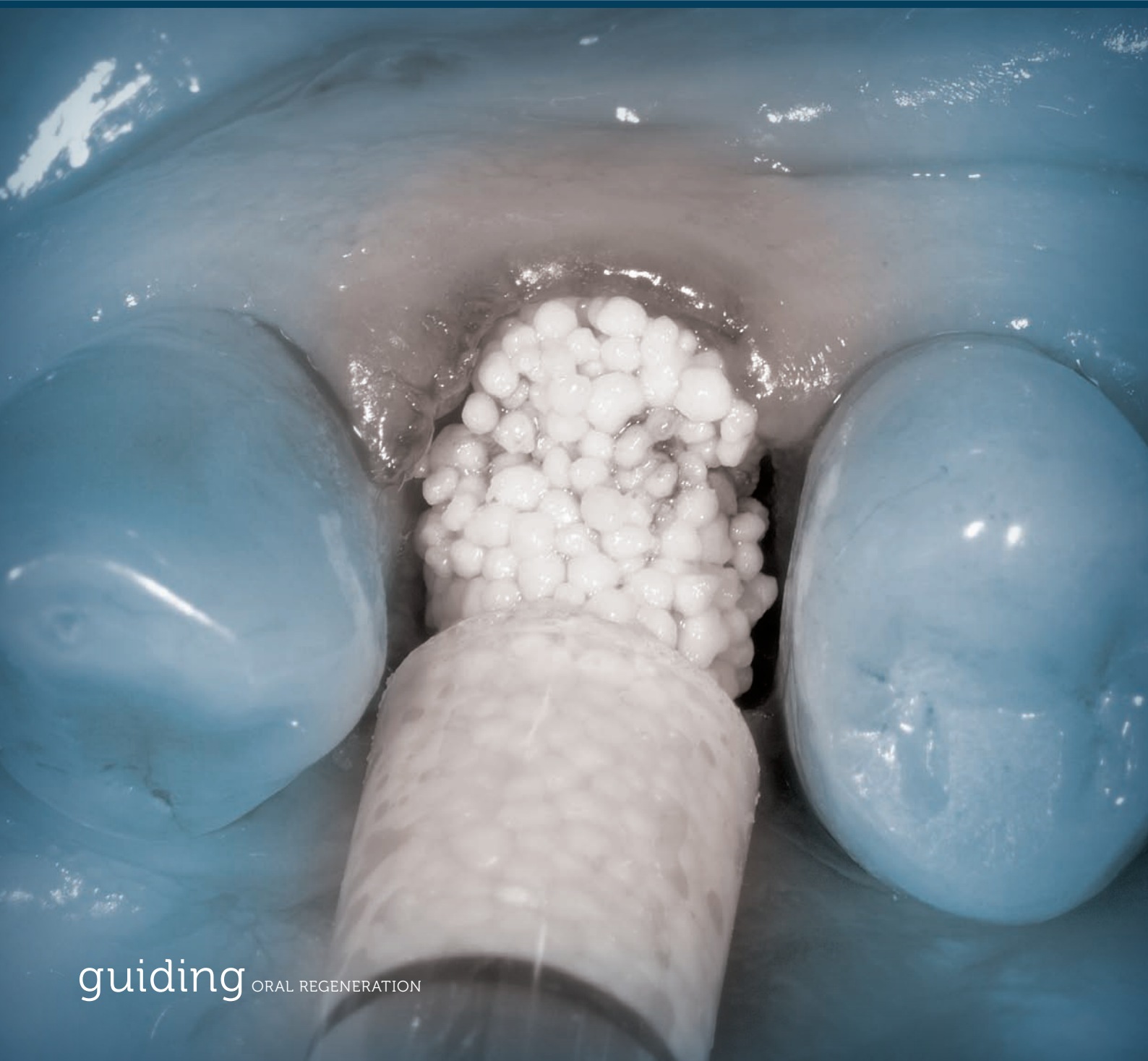

# Indication Guide **Ridge Preservation**

Scientific evidence, decision tree, treatment recommendations  
and case reports using synthetic biomaterials



---

# Contents

Evidence and Aim of this Indication Guide..... 3

GUIDOR Synthetic Biomaterials and GUM Pre- and Post-Surgical Care..... 4-5

Product Evidence ..... 6

Decision Tree for Treatment ..... 7

Step-by-step Guidelines for Minimally Invasive Ridge Preservation..... 8-9

Post-Surgical Care and Implant Placement.....10

Case reports ..... 11-25

Disclaimer..... 26

Cited References ..... 27

---

# Evidence and Aim of this Indication Guide

## Ridge preservation reduces alveolar atrophy following tooth loss

Tooth extraction generally results in anatomical changes and a reduction of the alveolar ridge due to a cascade of biological events that are triggered by the alveolar defect and the absence of the tooth (Araujo & Lindhe 2005, Van der Weijden et al. 2009). This remodelling process resulting in a significant loss of the alveolar ridge volume has been well described in the literature (Schropp et al. 2003, Van der Weijden et al. 2009, Avila-Ortiz et al. 2014). However, sufficient volume of the alveolar bone is essential to obtain optimal functional and aesthetic prosthetic reconstructions.

Most of the resorption occurs during the first 3 to 6 months followed by gradual reductions in dimensions thereafter. A broad systematic analysis of the relevant literature showed that vertical loss in the first 6 months equals about 1.2 mm (11–22% of the original height). In the buccolingual dimension, about 3.8 mm (29–63 % of original width) is lost (Tan et al. 2012). With physiological loss of hard and soft tissue following tooth extraction, proper axial alignment of the implant and aesthetically pleasing prosthetic options are challenging. To minimize alveolar atrophy in the course of wound healing, methods have been described that are summarized under the terms “socket preservation” or “ridge preservation”. They typically involve filling the socket with bone or bone graft substitute and/or covering it with a membrane.

### Ridge preservation procedures have the following objectives:

1. Preservation of the ridge profile – ridge preservation
2. Closing the wound after tooth extraction – wound care
3. Supporting bone formation in the area of the socket for implant placement – bone regeneration

The primary objective of ridge preservation is preserving the existing alveolar ridge contour by maintaining both the existing bone and soft tissue dimensions. This is not necessarily associated with new bone formation within the extraction socket. Scientific evidence shows that ridge preservation procedures are effective and can significantly reduce alveolar atrophies compared to spontaneous healing in the first 6 months (Vignoletti et al. 2012). Nonetheless, the alveolar bundle bone, in which the collagen fibres of the periodontium are anchored, is functionally dependent on the presence of a tooth root and is consequently absorbed following tooth loss (Araujo et al. 2005). Therefore, ridge preservation procedures cannot completely prevent loss of ridge volume following extraction, but they can significantly reduce it (Vignoletti et al. 2012, Avila-Ortiz et al. 2014). In many cases the resulting ridge contour can be sufficiently preserved to allow the placement of dental implants in a correct position without the need of additional simultaneous bone augmentation procedures (Cardaropoli et al. 2015).

Primary wound closure in ridge preservation requires mobilizing a flap that can lead to increased pain and swelling and causes changes in the mucosal anatomy. Therefore, less invasive methods, such as the use of a free soft tissue graft or open healing without primary wound closure have been described to preserve the ridge contour while providing excellent soft tissue aesthetics (Thoma et al. 2006; Aimetti et al. 2009; Gacic et al. 2009; Brkovic et al. 2011; Vignoletti et al. 2012). Consequently, ridge preservation should be considered as a valuable treatment option in a patient-centred treatment plan adapted to the individual patient’s anatomical situation as well as the functional and aesthetic objectives.

In order to align published evidence on ridge preservation with clinical experience in the daily practice with synthetic materials, clinical experts for ridge preservation met in July 2017 in Zurich\*. This indication guide consolidates both, scientific evidence on ridge preservation and practical considerations around the use of synthetic biomaterials predominantly in a minimally invasive approach.

The application of these indication guidelines for ridge preservation in the clinical practice is illustrated with original clinical cases demonstrating the use of GUIDOR synthetic biomaterials.

#### \* Participating clinical experts:

Prof. Dr. Wilfried Engelke: Göttingen, Germany  
Dr. Muzafar Bajwa: Frankfurt, Germany  
Dr. Alfonso Caiazzo: Salerno, Italy

Dr. Antonio Flichy-Fernández: Valencia, Spain  
Dr. Henrik-Christian Hollay: Munich, Germany  
Dr. Ashish Kakar: New Delhi, India

Dr. Minas Leventis: London, United Kingdom  
Dr. Marco Montanari: Forlì, Italy  
Dr. Angelo Troedhan: Vienna, Austria

# GUIDOR Synthetic Biomaterials and GUM Pre- and Post-Surgical Care

## GUIDOR *easy-graft* synthetic bone graft substitute

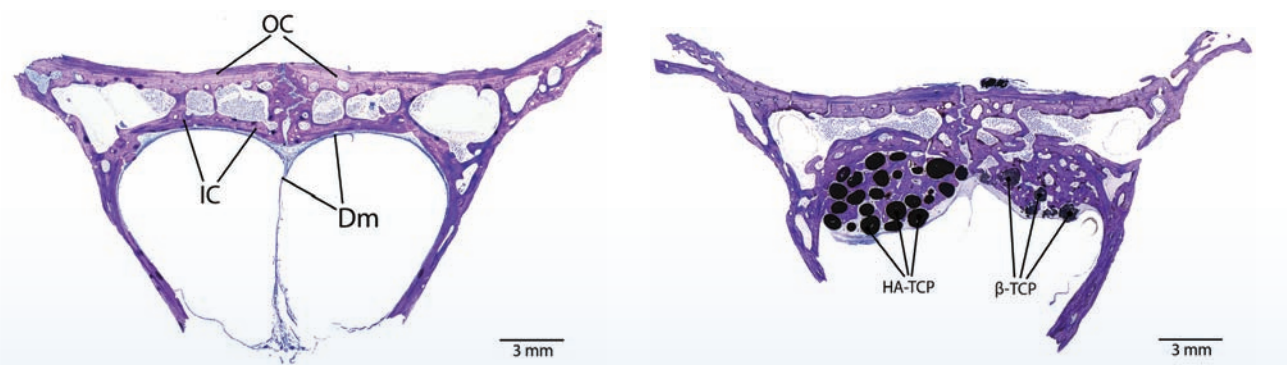
GUIDOR *easy-graft* is a synthetic bone augmentation material that is applied directly from the syringe into the defect. The mouldable adhesive granules can be shaped in the defect. When in contact with blood, the material hardens within minutes to form a porous defect analogue. GUIDOR *easy-graft* products are 100 % synthetic and do not contain substances of animal or human origin.

## GUIDOR *calc-i-oss* synthetic bone graft substitute

GUIDOR *calc-i-oss* is a synthetic bone augmentation material consisting of stable spherical granules that allow for a variety of application options such as: mixing with blood, mixing with blood preparation (e.g. PRP or CGF), mixing with autogenous bone or other bone graft materials. GUIDOR *calc-i-oss* products are 100% synthetic and do not contain substances of animal or human origin.

Product	GUIDOR <i>easy-graft</i> CLASSIC	GUIDOR <i>easy-graft</i> CRYSTAL	GUIDOR <i>calc-i-oss</i> CLASSIC	GUIDOR <i>calc-i-oss</i> CRYSTAL
Description	Mouldable adhesive granules	Mouldable adhesive granules	Granules	Granules
Material	Pure, 100% $\beta$ -TCP	Biphasic, 60% HA 40% $\beta$ -TCP	Pure, 100% $\beta$ -TCP	Biphasic, 60% HA 40% $\beta$ -TCP
Resorption behaviour	Fully resorbable	Partially resorbable	Fully resorbable	Partially resorbable
<i>in situ</i> hardening	+	+	-	-
Application	Syringe	Syringe	Vial	Vial
Possibility to mix with other materials (blood, bone, ...)	-	-	+	+
Granule size	500 - 1000 $\mu$ m	450 - 1000 $\mu$ m	315 - 500 $\mu$ m 500 - 1000 $\mu$ m	450 - 1000 $\mu$ m

## GUIDOR *easy-graft* CRYSTAL versus GUIDOR *easy-graft* CLASSIC



Data published by Valdivia-Gandur et al. 2016 show in a rabbit model that both, GUIDOR *easy-graft* CRYSTAL (HA-TCP) and GUIDOR *easy-graft* CLASSIC ( $\beta$ -TCP) can maintain the volume and support the formation of new bone even under physiological pressure comparable to the situation encountered in a sinus floor elevation. Frontal cut of samples from rabbit calvaria. Left: control specimen without biomaterial placement (sham operated). Right: specimen with the bilateral insertion of HA-TCP and  $\beta$ -TCP. Toluidine blue histology; OC: outer cortex; IC: inner cortex; Dm: dura mater.

---

## GUM pre- and post-surgical care

GUM® PAROEX® professional plaque control products contain no alcohol and are formulated with:

- Chlorhexidine Digluconate (CHX), the professional reference for plaque control that promotes gum health and has a broad antiseptic spectrum.
- Cetylpyridinium Chloride (CPC), an anti-plaque and toxin neutralizing agent that enhances the effects of Chlorhexidine.

**GUM® PAROEX® 0.12% Mouthrinse** (0.12% CHX + 0.05% CPC). Professional plaque control for optimal gum health.

GUM® PAROEX® Intensive Action mouthrinse is ideal for plaque control pre- and post-oral surgery, tooth extraction and implant placement.

**GUM® PAROEX® Toothpaste Gel** (0.12% CHX + 0.05% CPC) for Intensive Action. GUM® PAROEX® toothpastes have been formulated without anionic foaming agents (such as Sodium Lauryl Sulfate) in order to maximize plaque control benefits and to reduce possible irritation of the oral mucosa.

**GUM® Post-Operation Toothbrush.** An ultrasoft toothbrush with 0.10 mm bristles. Ideal for post-surgical cleaning, gum disease, mouth irritations, extractions, implants and grafts.

**GUM® Technique® PRO Toothbrush.** Deep and gentle cleaning for better gum health. Scientifically tested to provide superior plaque removal in the areas the most difficult to clean: between the teeth, along and below the gumline.



For more information on GUIDOR products, please visit [www.guidor.com](http://www.guidor.com) or contact our local affiliate.



For more information on GUM products, please visit [www.sunstargum.com](http://www.sunstargum.com) or contact our local affiliate.

---

# Product Evidence

## Clinical evidence for GUIDOR *easy-graft* in Ridge Preservation

Substantial clinical evidence exists documenting the effectiveness of GUIDOR *easy-graft* CLASSIC (El Sayed et al. 2015, Leventis et al. 2016, Decco et al. 2017, Saito et al. 2017) and GUIDOR *easy-graft* CRYSTAL (Jurisic et al. 2013, Kakar et al. 2017) for ridge preservation without achieving primary closure or covering the site with a dental membrane or a soft tissue punch while allowing for a subsequent implant placement. Clinical studies on ridge preservation with GUIDOR *easy-graft* show well preserved bone contours and a minimal reduction at the bone level as indicated by a minimal bone ridge width reduction of  $0.79 \pm 0.73$  mm at a level of 2 mm below the bony crest (Kakar et al. 2017). Another study evidenced a minimal reduction in ridge height of less than 10% after ridge preservation (Saito et al. 2017). These data are further corroborated at the soft tissue level showing a minimal loss of soft tissue contour after 6 months (Decco et al. 2017). Excellent new bone formation was evident by histological data obtained by these studies showing that GUIDOR bone graft substitutes support sufficient new bone formation for implant placement. Mean values of newly formed bone in the grafted sockets ranged between 21.3 up to 32.2 % (Jurisic et al. 2013, Leventis et al. 2016, Kakar et al. 2017), similar to values found for other types of bone graft materials (Cordaro et al. 2008).

Moreover, publications highlighted the good secondary soft tissue healing using GUIDOR *easy-graft* without membrane coverage or primary soft tissue closure in the case of intact sockets (Leventis et al. 2016, Saito et al. 2017, Kakar et al. 2017).

## Pre-clinical evidence of GUIDOR *easy-graft*

Naenni et al. studied the effect of ridge preservation with GUIDOR *easy-graft* CRYSTAL and a competitor biphasic calcium phosphate material compared to a control group without bone graft substitute in tooth extraction sites of beagle dogs at 4, 8 and 16 weeks (Naenni et al. 2017). The authors found that the ridge preservation was successful to a similar extent in maintaining the buccal contour with both materials and more favourable compared to spontaneous healing without bone graft substitute.

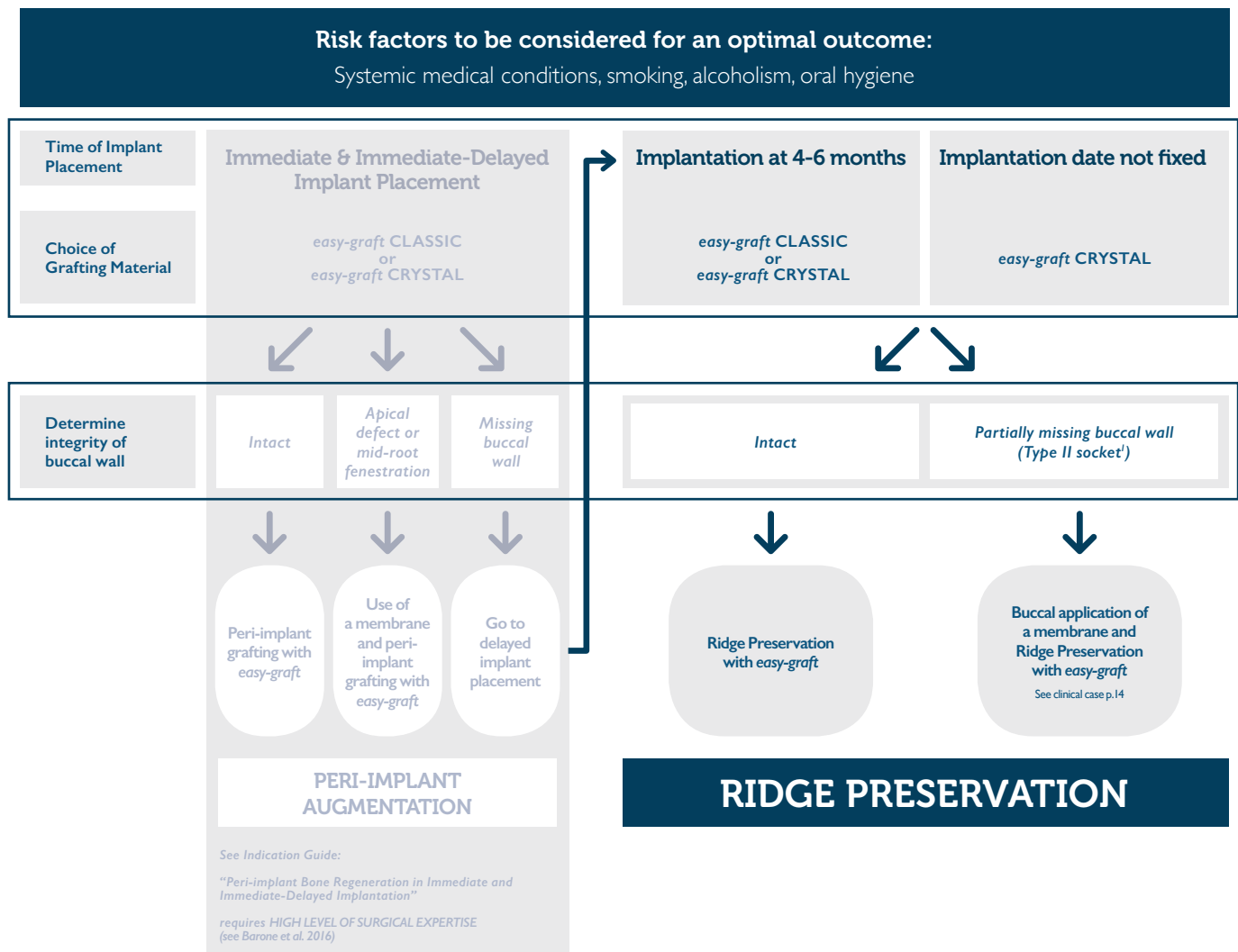
Several pre-clinical studies compared the bone formation of GUIDOR *easy-graft* products with different materials available on the market such as xenografts or other synthetic materials in critical size of cranial bone defect models of rats and rabbits. The publications consistently evidence that the synthetic GUIDOR bone graft substitutes are equivalent to other materials in terms of new bone formation and biocompatibility (Schmidlin et al. 2013, Yip et al. 2015, Bizenjima et al. 2016).

An *in vivo* study in goats showed good bone regeneration and implant integration when GUIDOR bone graft substitutes were applied with simultaneous implant placement. It was evident that peri-implant augmentation with GUIDOR *easy-graft* CLASSIC and GUIDOR *easy-graft* CRYSTAL is effective providing excellent bone-to-implant contact comparable to autologous bone chips, which are considered the gold standard (Neldam et al. 2017).

Data published by Valdivia-Gandur et al. in a rabbit model show that both, GUIDOR *easy-graft* CLASSIC and GUIDOR *easy-graft* CRYSTAL can maintain the volume and support the formation of new bone even under physiological pressure comparable to the situation encountered in sinus floor elevation. The authors further investigated the graft resorption, volume preservation and potential of new bone formation potential and showed that the percentage of new bone was higher in the fully resorbable GUIDOR *easy-graft* CLASSIC, which provided more space for bone ingrowth while resorbing. On the other hand, the augmented volume was better preserved under physiological pressure and the amount of lamellar bone was increased when the biphasic, HA-containing GUIDOR *easy-graft* CRYSTAL was used (Valdivia-Gandur et al. 2016).

# Decision Tree for Treatment

## Treatment Options for Extraction Sites



### Indications for Ridge Preservation

- Intact sockets and sockets with mild marginal injury to the buccal plate (see "Socket evaluation")
- Following extraction of single-rooted teeth and multi-rooted teeth with preserved interradicular septum

### Relative indications for Ridge Preservation

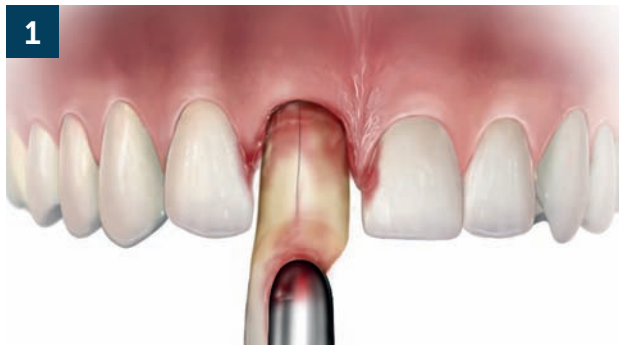- Small apical perforations in the buccal plate
- Interradicular bone loss (e.g. as a result of inflammatory processes)

### Contraindications for Ridge Preservation

- Acutely infected (suppurative) socket
- Non vital tooth with apical fistula
- If no bleeding from the bone is achieved
- Major injury or loss of the buccal plate: surgical bone augmentation / guided bone regeneration is required

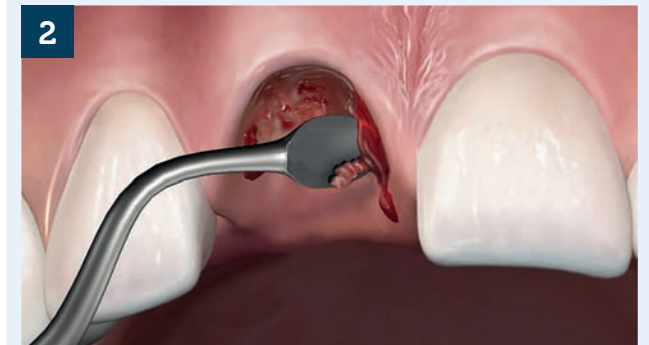
<sup>1</sup>Type II socket: facial soft tissue is present but the buccal plate is partially missing following extraction of the tooth (Elian et. al. 2007)

# Step-by-step Guidelines for Minimally Invasive Ridge Preservation



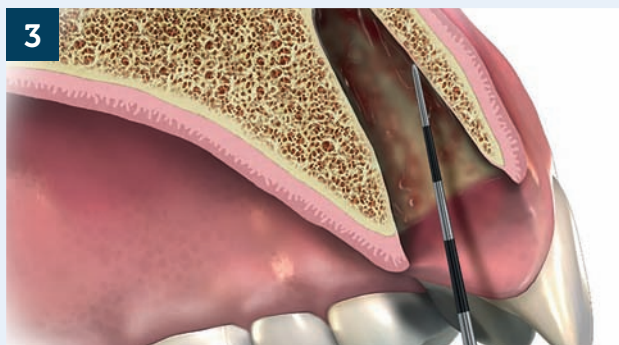
## Atraumatic Tooth Extraction

- Anterior: preserving the buccal plate
- Molars: preserving the buccal plate and interradicular septum



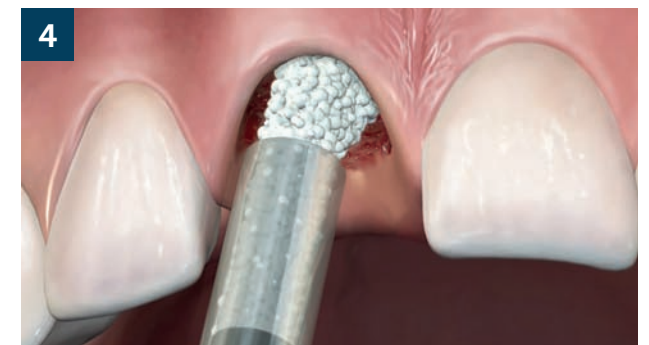## Socket Preparation

- Socket Cleaning: remove all granulation tissue
- Induce bleeding for bone regeneration



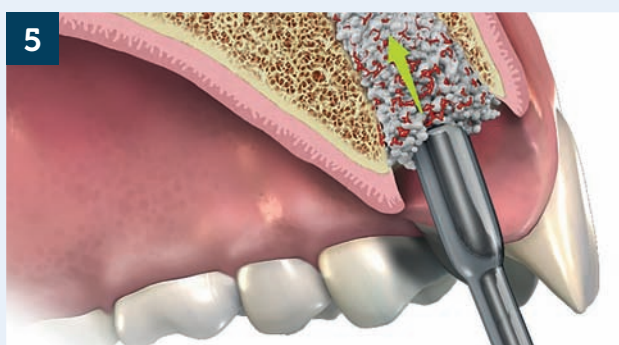
## Socket Evaluation

- Visual Inspection: rinsing with saline and suction
- Periodontal Probe: assess buccal wall integrity and soft tissue remnants
- Proper bleeding? If not, curette the walls



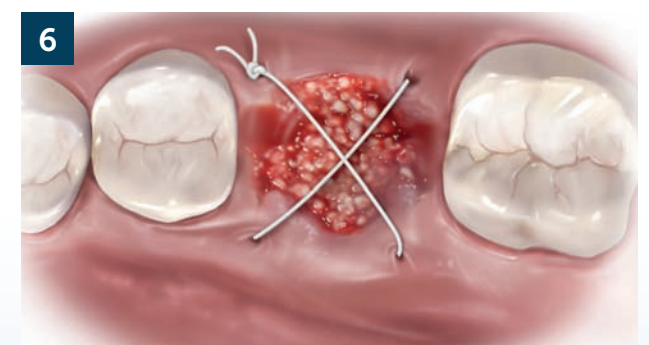
## Graft Application

- Intact buccal wall: fill with *easy-graft* only



## Graft Adaptation

- Filling level: fill the material at least to the crestal bone level  
→ Overfilling does not harm
- Compression: compress graft firmly until hardened (< 1min)



## Site Closure (Suturing)

Application of cross-suture to:

- stabilize the grafted area
- approximate the wound edges

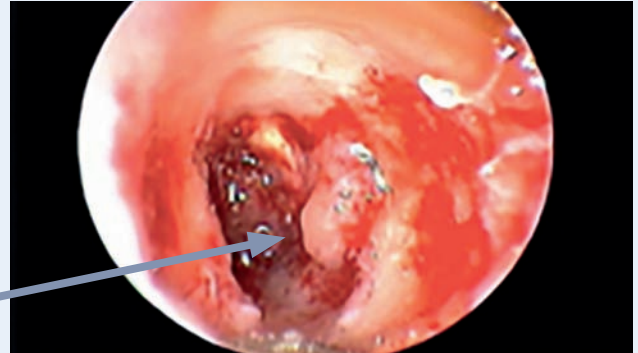Optional: cover site with a collagen fleece

## 2 Socket Preparation: Socket Cleaning

### Important:

- Consider at least 3-5 min for cleaning of one socket
- Use a sharp curette or a round burr in circular way against the turning direction from apex to top
- Take care to clean all four walls and the apex

Endoscopic view of an extraction site with remaining soft tissue at the apex that needs to be removed.<sup>2#</sup>

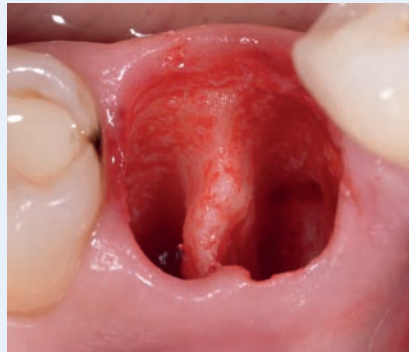

<sup>2</sup> See also: Beltrán et al. 2012

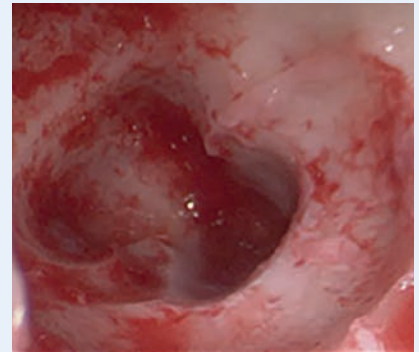
## 3 Socket Evaluation: Visual inspection

### Important:

- Rinse with saline and suction for proper inspection
- Probe with periodontal probe if all soft tissue has been removed



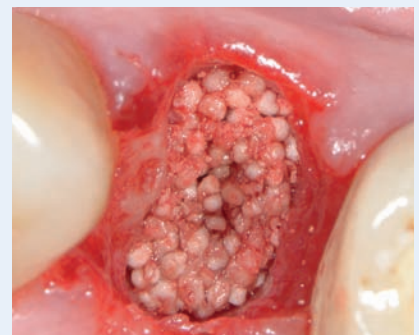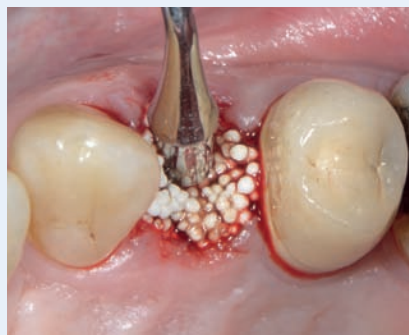Clean Socket: Clinical Picture\*



Clean Socket: Endoscopy<sup>#</sup>

## 5 Graft Adaptation: Compression

Dense compression of *easy-graft* with plunger after application\*. Alternatively, the plunger of the syringe can be used. *easy-graft* should form a stable and dense surface protecting the wound and uptake of blood should be visible.



\* Picture: Dr. Leventis; <sup>#</sup> Picture: Prof. Engelke



### Post-surgical Care and Implant Placement

Post-surgical plaque control using Sunstar GUM oral care products and considerations during soft tissue healing are detailed on page 10.

# Post-Surgical Care and Implant Placement

## Recommended Post-Surgical Plaque Control




### SOFT TISSUE HEALING

Surgery    1 week    2 weeks    4 weeks    6 weeks


Soft diet no chewing or stress wound area



CHX rinse \*



CHX toothpaste gel




Post-surgical toothbrush

No brushing on site until suture removed



Ultra-soft toothbrush

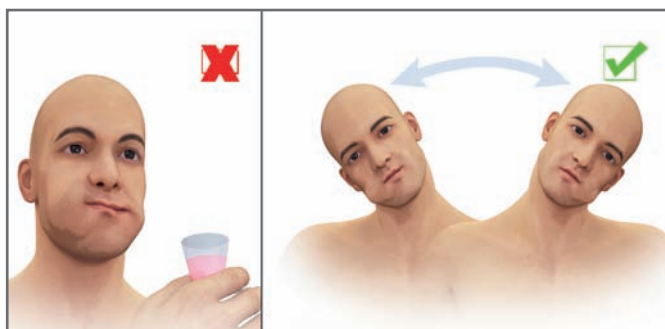

Interdental brush and

normal brushing with a soft toothbrush



#### \*Use of Oral Mouth Rinse



Antibacterial oral rinse containing chlorhexidine digluconate (such as GUM® PAROEX®) should be used before and after the surgery to reduce the microbial flora in the oral cavity and post-surgery inflammatory complications.

The patient should not apply too much force with the cheek muscles during rinsing (left). Advise patient to gently rinse with antibacterial oral rinse by moving the head from one side to the other (right).

#### Antibiotic therapy

Antibiotic therapy may be provided at the discretion of the practitioner and should follow current standards of care for pre- and post-medication.

### Important Consideration during Soft Tissue Healing and Implant Placement

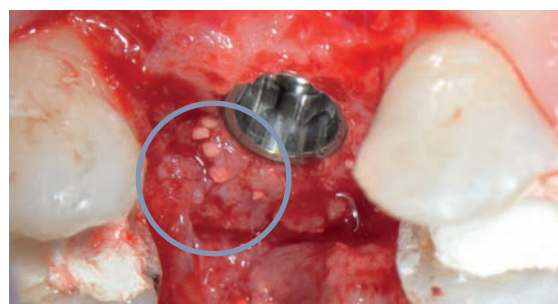#### During Soft Tissue Healing:

- Do not scrape off loose particles during soft tissue healing.
- The patient should be informed that individual granules can be lost until the mucosa is completely closed.

#### At re-entry for Implant Placement:

- Wait 4 to 6 months, depending on the individual healing and the socket dimension.
- Complete regeneration of the entire socket takes about 12 months.
- **Visibility of granules:** after re-entry, granules might be visible  
→ Do not scrape off visible particles

#### Re-entry: Visibility of Granules



Upon re-entry, granules may be seen in the soft tissue and embedded into newly formed bone because of their distinct white colour. (Picture Dr. Leventis)

---

# Case Reports

## Ridge Preservation

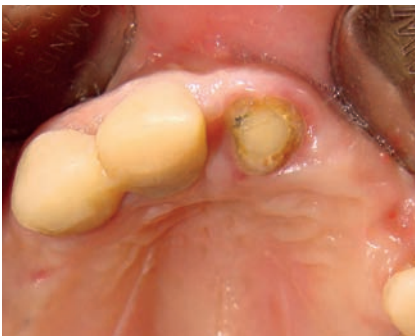Dr. Mario Kirste: Tooth 21.....	Pg 12 & 13
Prof. Antonio Barone, Dr. Lucille Trottet, Dr. Fortunato Alfonsi: Tooth 11.....	Pg 14 & 15
Dr. Sandro Siervo: Tooth 24.....	Pg 16 & 17
Dr. Minas Leventis: Tooth 15.....	Pg 18 & 19
Dr. Minas Leventis: Tooth 16.....	Pg 20 & 21
Dr. Ashish Kakar: Teeth 45, 46.....	Pg 22 & 23
Dr. Christine Romagna: Tooth 37.....	Pg 24 & 25

# Ridge Preservation

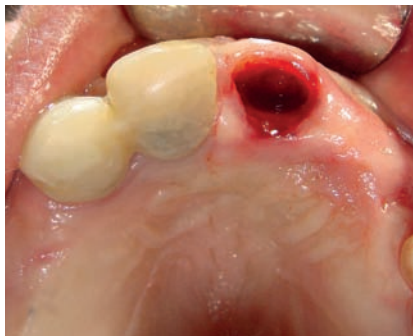## Frontal tooth

Dr. Mario Kirste, Frankfurt (Oder), Germany

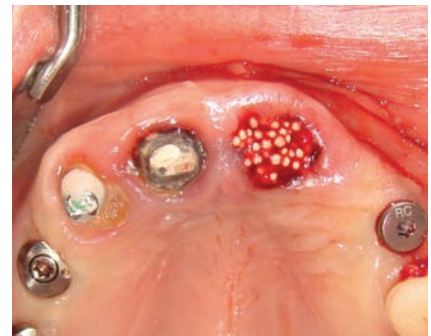Patient	Female, 60 years old
Position	Maxillary left first incisor, tooth 21
Initial situation	Tooth with preceding root canal treatment and periapical lucency.
Material used	GUIDOR <i>easy-graft</i> CLASSIC



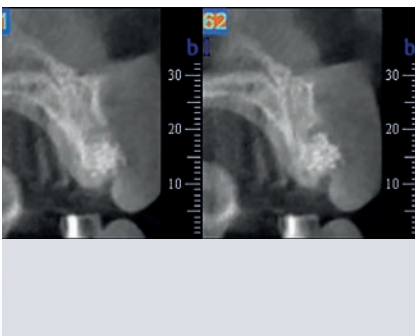
**Fig. 1** Situation before extraction. The maxillary incisor with root canal treatment is deemed not worth preserving.



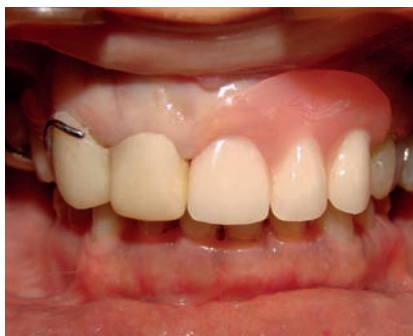**Fig. 2** Socket after atraumatic extraction and before cleaning and conditioning. The buccal bone plate has been preserved.



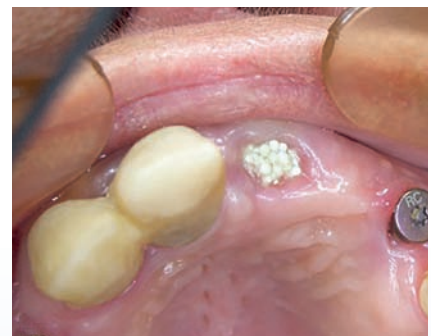**Fig. 3** Extraction socket filled and condensed with GUIDOR *easy-graft* CLASSIC. Filled to gingival level.



**Fig. 4** Digital volume tomography: bucco-palatal cross-section, post-operatively.



**Fig. 5** Postoperative prosthetic restoration.



**Fig. 6** Situation after two weeks.

## Surgical Approach

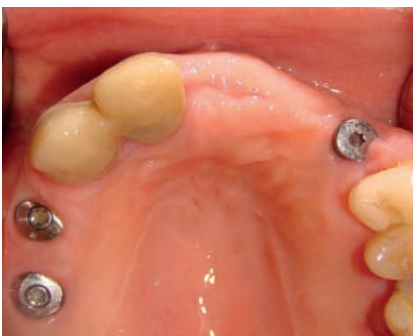Ridge preservation with implant placement at 7 months.

## Key Steps

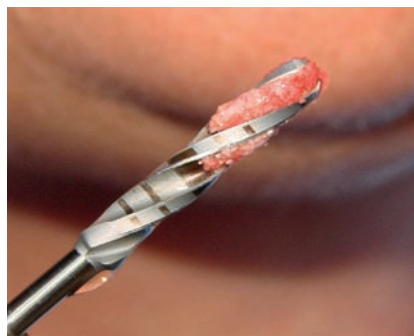
- Atraumatic extraction of tooth 21 and cleaning
- Ridge preservation with GUIDOR *easy-graft* CLASSIC
- Implant placement 7 months post-op
- Loading of implant 12 months after ridge preservation

## Follow-up

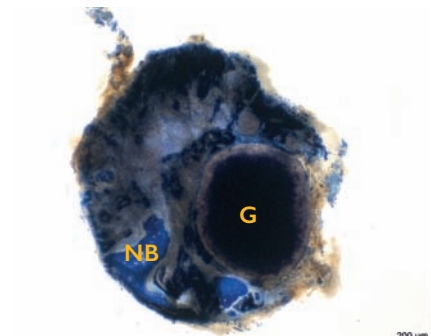
1 year



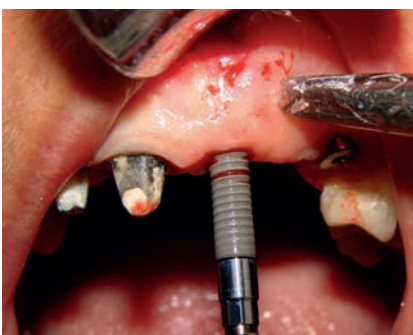**Fig. 7** Situation after 7 months before implant placement.



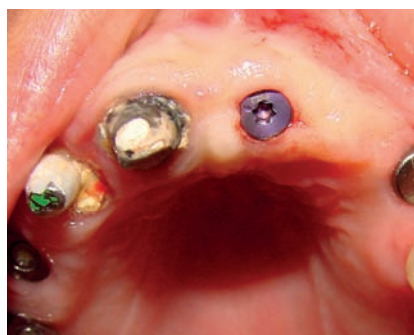**Fig. 8** Preparation of the implant bed with surgical guide: implant drill with vital material.



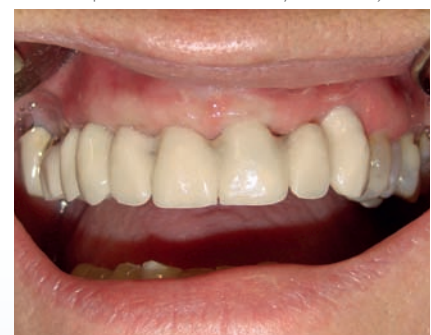**Fig. 9** Transversal cut through the drill core. Bone graft substitute granules (G) surrounded by newly formed bone (NB). The dark coloration of the granules indicates strong colonisation with cells (Histology: Stübinger-S and Kämpf K, MSRU, University of Zurich).



**Fig. 10** Implant placement at 7 months after ridge preservation (Straumann SLActive 4.1x 12mm).



**Fig. 11** After implant placement and insertion of the healing cap.



**Fig. 12** Situation 5 months after implantation: loading of the implant, placement of a long-term temporary restoration. Note: three months after implant placement, the remaining right maxillary incisor was also extracted and ridge preservation was performed.

# Ridge Preservation

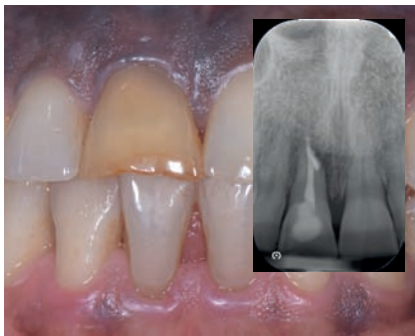## Frontal tooth

Prof. Antonio Barone, Geneva, Switzerland

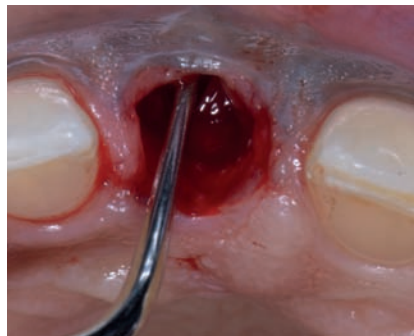
Dr. Lucille Trottet, Geneva, Switzerland

Dr. Fortunato Alfonsi, Sulmona, Italy

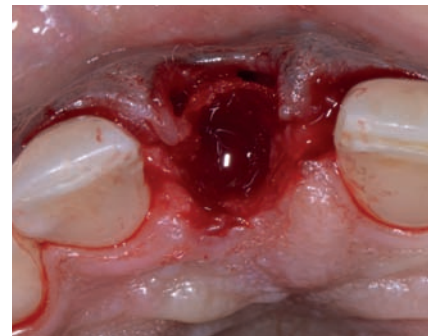
Patient	Female, 49 years old
Position	Frontal right first incisor, tooth II
Initial situation	Hopeless tooth in the aesthetic zone
Material used	GUIDOR <i>matrix barrier</i> , GUIDOR <i>easy-graft</i> CRYSTAL



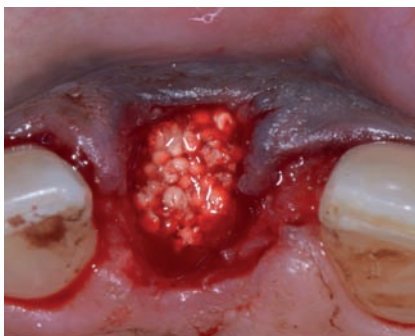
**Fig. 1** Pre-op clinical view and corresponding x-ray showing the situation of tooth II that needs to be extracted.



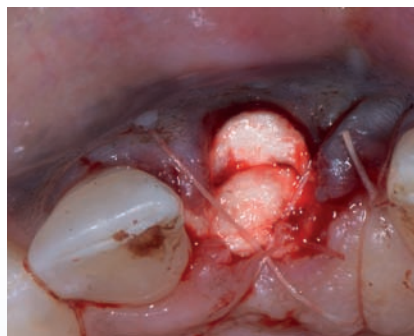
**Fig. 2** Tooth extraction without raising a flap. The extraction socket was thoroughly debrided to remove all soft tissue. Clinical situation after tooth extraction with buccal dehiscence.



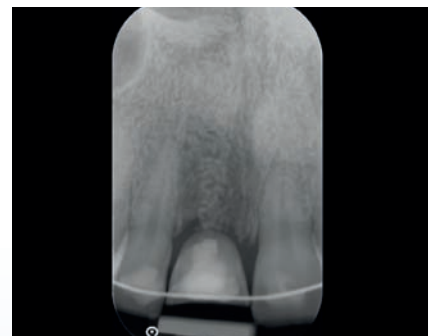**Fig. 3** Placement of a GUIDOR *matrix barrier* on the outside of the defective buccal plate to cover the buccal dehiscence (MICCT, p. 9).



**Fig. 4** Ridge preservation with GUIDOR *easy-graft* CRYSTAL.



**Fig. 5** Covering of the site with a collagen-fleece and approximation of the soft tissue with a cross-mattress silk suture.



**Fig. 6** Control x-ray after the ridge preservation procedure.

## Surgical Approach

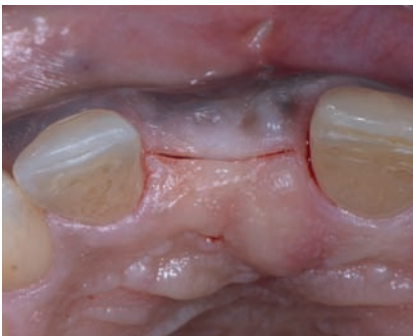Coverage of buccal dehiscence with resorbable membrane and ridge preservation with implant placement at 6 months

## Key Steps

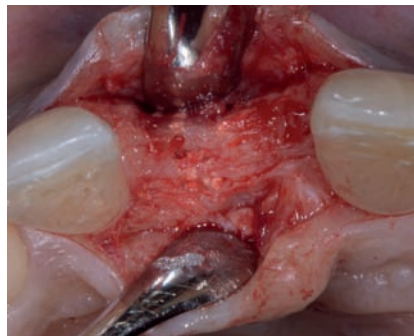
- Atraumatic tooth extraction without raising a flap and thorough debridement of socket
- Placement of GUIDOR *matrix barrier* according to the modified ice cream cone technique
- Ridge preservation with GUIDOR *easy-graft* CRYSTAL
- Implant placement at 6 months
- Provisional restoration 4.5 months after implant placement

## Follow-up

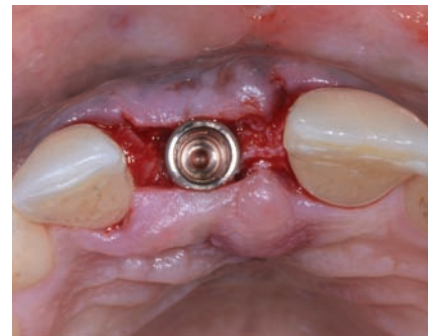1 year after ridge preservation



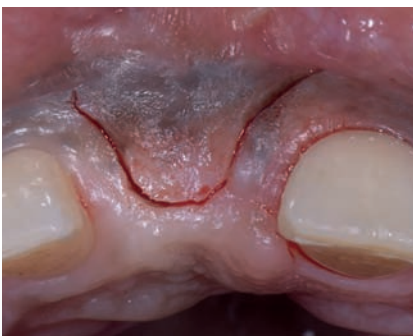**Fig. 7** Clinical situation after 6 months of healing before flap opening.



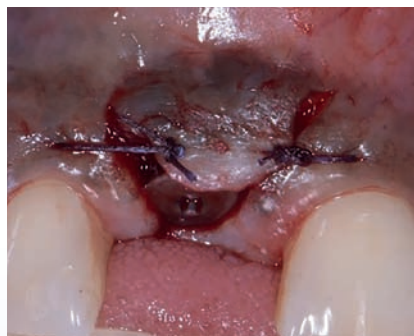**Fig. 8** Newly formed bone at 6 months re-entry. Adequate preservation of the ridge dimension can be seen.



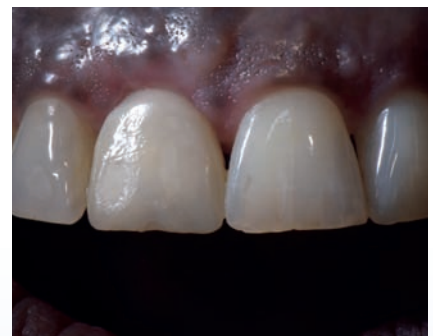**Fig. 9** Implant placement at 6 months.



**Fig. 10** Occlusal view 4 months after implant placement at second-stage surgery for the provisional restoration.



**Fig. 11** Situation after surgery with a healing abutment and the sutured flap.



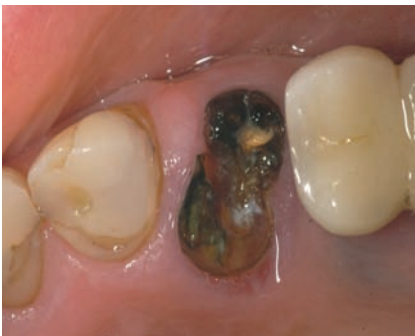**Fig. 12** Situation with restoration in place 1 year after ridge preservation.

# Ridge Preservation

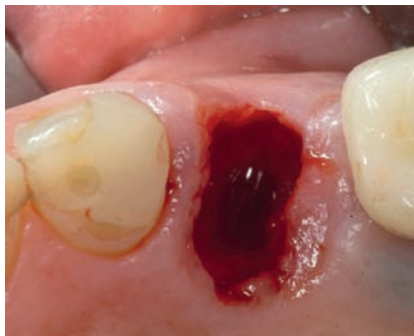## Premolar tooth

Dr. Sandro Siervo, Milano, Italy

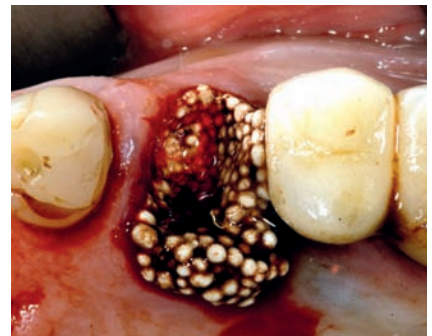Patient	Female, 55 years old
Position	Maxillary left first premolar (24)
Initial situation	24 with deep caries and periodontal damage judged as hopeless and to be extracted.
Material used	GUIDOR <i>easy-graft</i> CRYSTAL



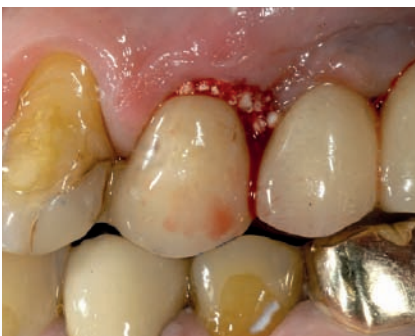**Fig. 1** Initial situation with hopeless maxillary first premolar (24).



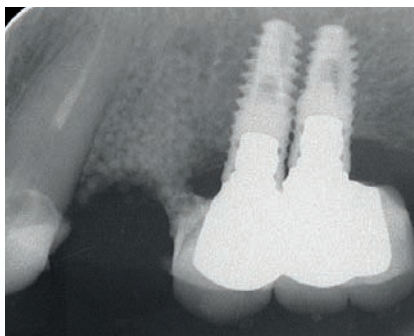
**Fig. 2** Atraumatic tooth extraction.



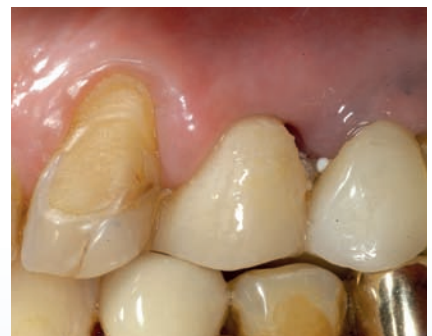**Fig. 3** Ridge preservation with GUIDOR *easy-graft* CRYSTAL.



**Fig. 4** Coverage of site with temporary ovate pontic according to "Bonner Konzept".<sup>1,2</sup>



**Fig. 5** Control X-ray after ridge preservation.

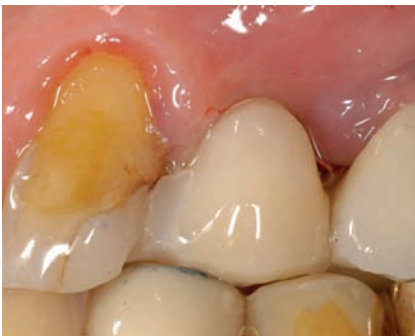

**Fig. 6** Clinical situation after 3 weeks.

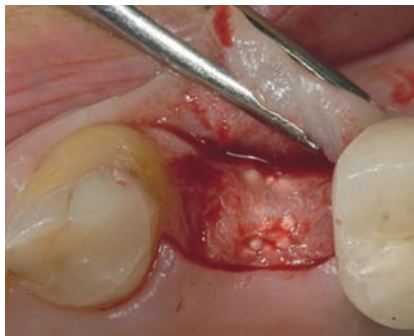<sup>1</sup> Lückerrath W: Nuovo protocollo chirurgo-protesico minimamente invasivo - Il "Bonner Konzept" [Modern procedure for the creation of an ovate pontic. A new, minimally invasive surgical-prosthetic protocol - The "Bonner Konzept"]. Il Dentista Moderno (2017) 2017 (1): 58-63

<sup>2</sup> Lückerrath W, Röder L and Enkling N: The Effect of Primary Stabilization of the Graft in a Combined Surgical and Prosthodontic Ridge Preservation Protocol: A Prospective Controlled Clinical Pilot Study. International Journal of Periodontics & Restorative Dentistry (2018) 38(3).

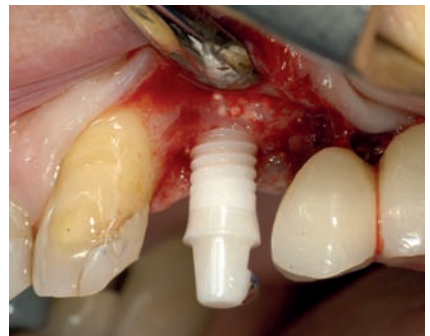Surgical Approach	Ridge preservation with temporary pontic
Key Steps	<ul style="list-style-type: none"> <li>• Atraumatic tooth extraction</li> <li>• Ridge preservation with GUIDOR <i>easy-graft</i> CRYSTAL</li> <li>• Coverage of site with temporary ovate pontic according to "Bonner-Konzept"</li> <li>• Implantation 7 months after Ridge Preservation</li> </ul>
Follow-up	2 years



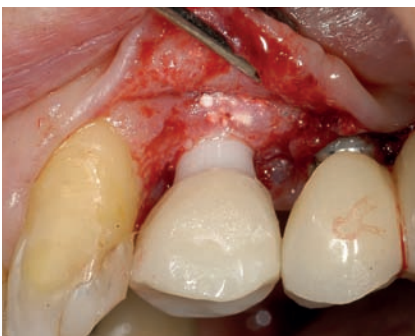**Fig. 7** Clinical situation after 1 month.



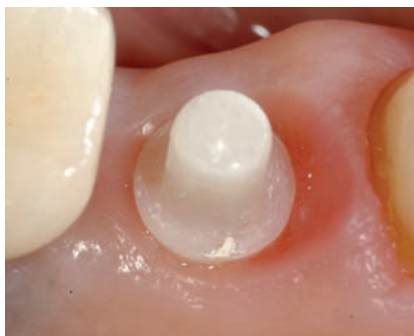**Fig. 8** Situation with open flap at 7 months.



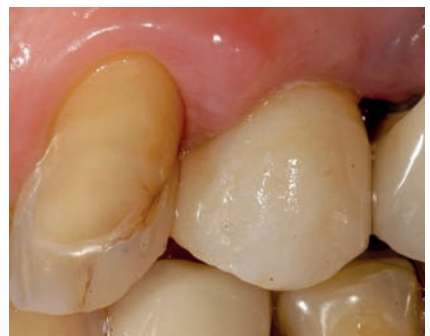**Fig. 9** Implant placement (Straumann, FC Zirconia, Implant 4.1 x 10 mm).



**Fig. 10** Situation with open flap at implant placement and temporary restoration, 7 months after ridge preservation.



**Fig. 11** Clinical situation after 3 months of healing.



**Fig. 12** Clinical situation with final restoration in place 25 months after ridge preservation.

# Ridge Preservation

## Premolar tooth

Dr. Minas Leventis, London, United Kingdom

Patient	Female, 23 years old
Position	Maxillary right second premolar tooth I5
Initial situation	Hopeless tooth due to extensive caries
Material used	GUIDOR <i>easy-graft</i> CLASSIC

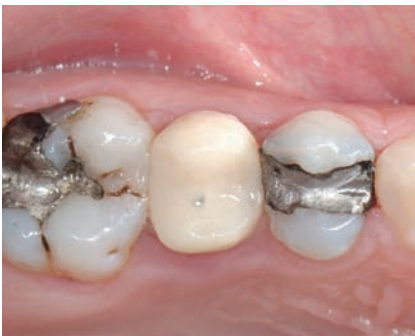

Fig. 1 Pre-op clinical view.

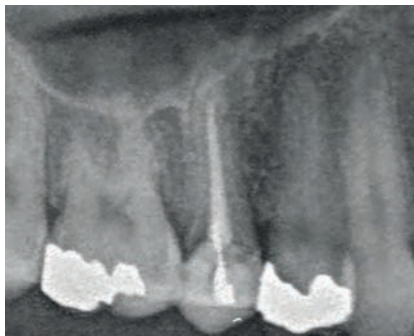


Fig. 2 Pre-op radiograph.

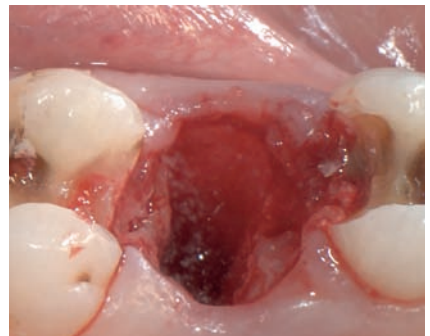


Fig. 3 Atraumatic extraction.

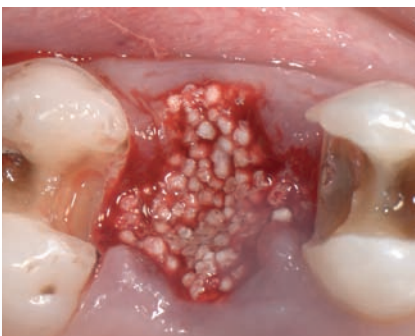

Fig. 4 Ridge preservation with GUIDOR *easy-graft* CLASSIC.

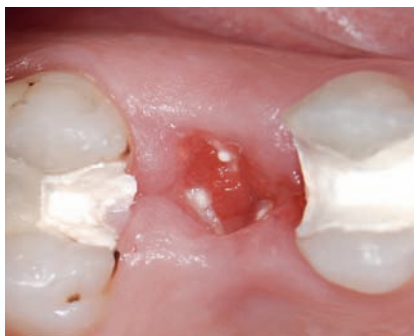

Fig. 5 Clinical result 3 weeks post-op. Gradual proliferation of the epithelium over the grafted site.

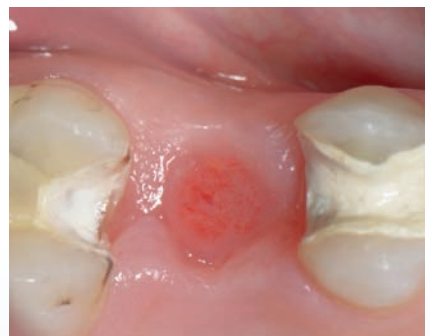

Fig. 6 Clinical result 3 months post-op. Grafted area is covered with newly formed keratinized epithelium.

## Surgical Approach

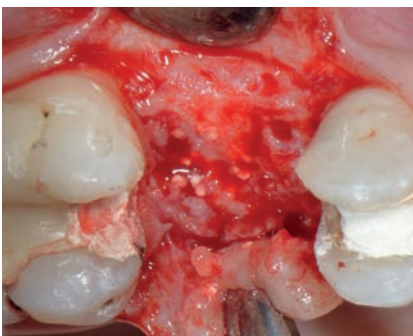Ridge preservation with implant placement at 4 months

## Key Steps

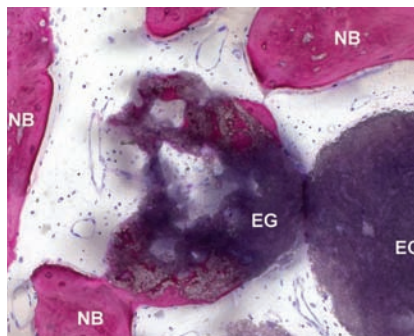
- Atraumatic tooth extraction and socket cleaning
- Ridge preservation with GUIDOR *easy-graft* CLASSIC without primary closure
- Acrylic provisional bridge bonded to the adjacent teeth
- Implant placement at 4 months
- Crown placement at 8 months

## Follow-up

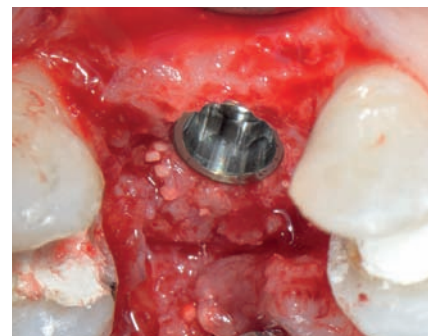
3.5 years after loading



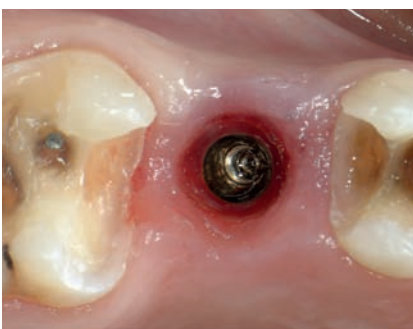**Fig. 7** Newly formed bone at 4 months re-entry. Adequate preservation of the ridge dimension can be seen.



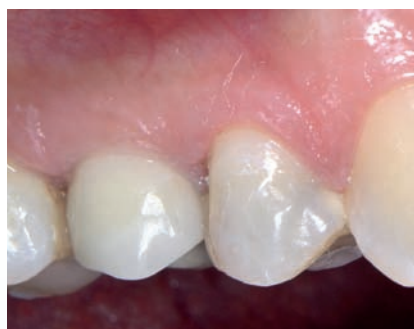**Fig. 8** Histological analysis of bone core biopsy at 4 months. 27.4 % newly formed bone, 15.6 % residual bone graft material.



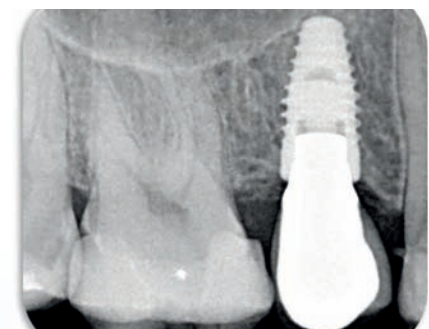
**Fig. 9** Implant placement at 4 months.



**Fig. 10** A healing abutment was set 3 months after implant placement. Situation after allowing the soft tissue to mature for 4 weeks.



**Fig. 11** Clinical situation after crown placement at 8 months.



**Fig. 12** Final radiograph 3.5 years after loading. No residual particles of the grafting material are detected and the implant is surrounded by vital bone.

# Ridge Preservation

## Molar tooth

Dr. Minas Leventis, London, United Kingdom

Patient	Female, 42 years old
Position	Maxillary right first molar tooth I6
Initial situation	Non-restorable I6 due to fracture
Material used	GUIDOR <i>easy-graft</i> CLASSIC

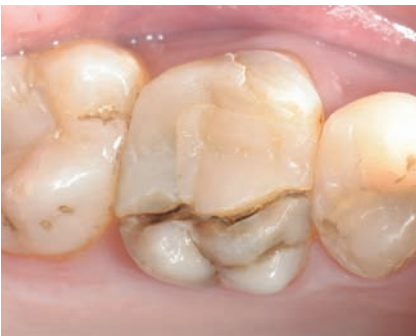

Fig. 1 Initial clinical situation with fractured tooth I6.

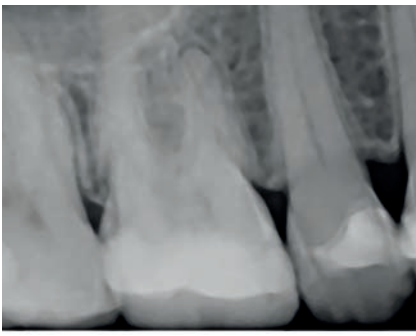


Fig. 2 Pre-op X-ray.

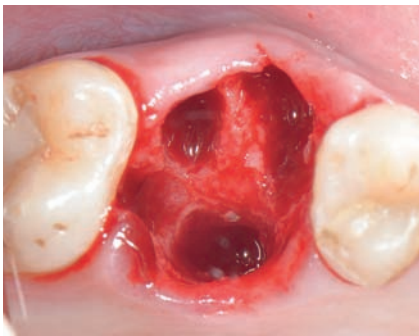


Fig. 3 Atraumatic extraction after sectioning of the roots.

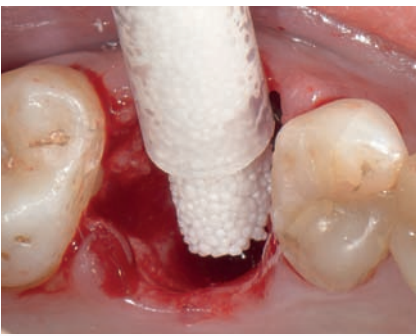


Fig. 4 Ridge preservation with GUIDOR *easy-graft* CLASSIC.

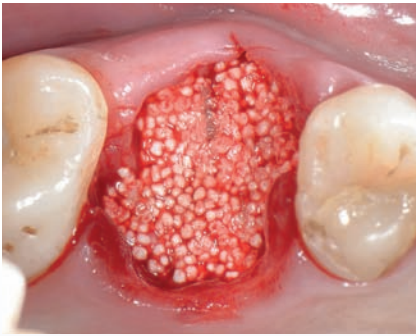


Fig. 5 The material was condensed.

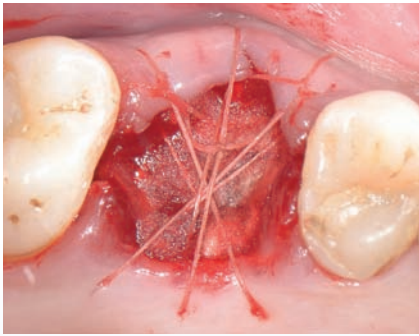


Fig. 6 Haemostatic dressing material placed over the top and suturing. No flap elevation and no primary closure was performed.

#### Surgical Approach

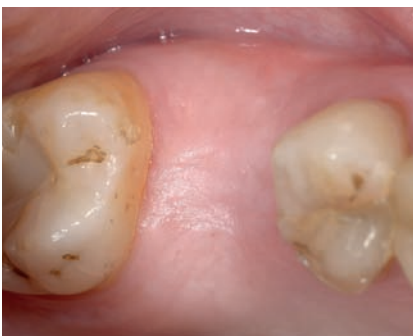Ridge preservation with implant placement at 5 months

#### Key Steps

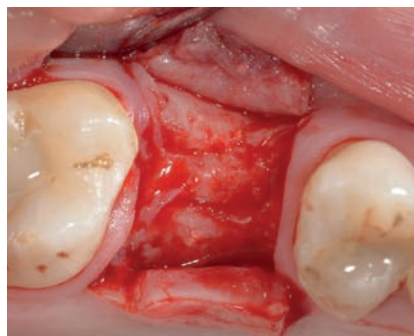
- Atraumatic extraction of tooth 16
- Ridge preservation with GUIDOR *easy-graft* CLASSIC
- Coverage with haemostatic dressing material. No flap elevation and no primary closure
- Implant placement 5 months after ridge preservation
- Crown placement 5 months after implant placement

#### Follow-up

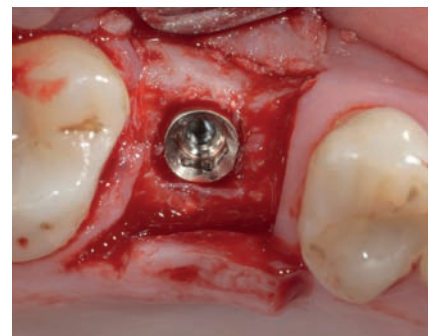10 months



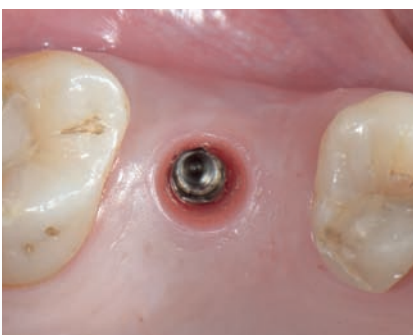
**Fig. 7** Clinical situation 3 months post-op. The site is covered by newly-formed keratinized tissue.



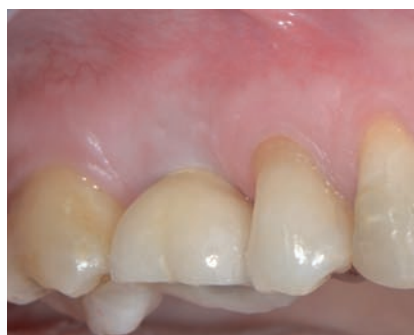**Fig. 8** Situation at re-entry (5 months).



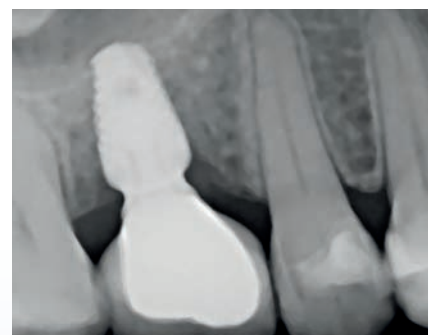
**Fig. 9** Implant placement 5 months after ridge preservation: Paltop Advanced 5.0 x 8 mm implant.



**Fig. 10** Clinical situation after removal of the healing abutment 5 months after implant placement. Resonance frequency analysis shows an implant stability quotient of 82.



**Fig. 11** Clinical Situation after fitting of the implant crown 10 months after ridge preservation.



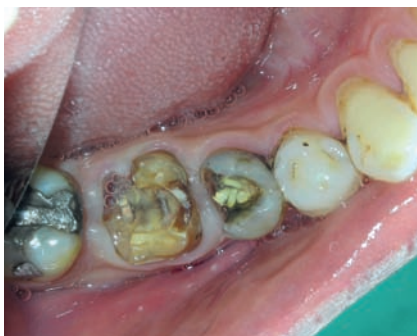**Fig. 12** X-ray after crown placement and with final restoration in place.

# Ridge Preservation

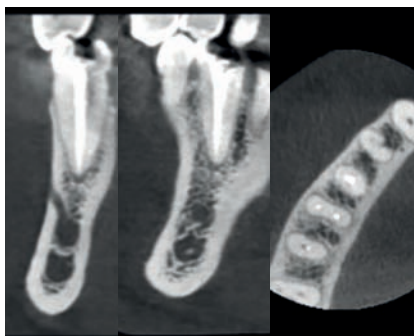
## Premolar and Molar tooth

Dr. Ashish Kakar, New Delhi, India

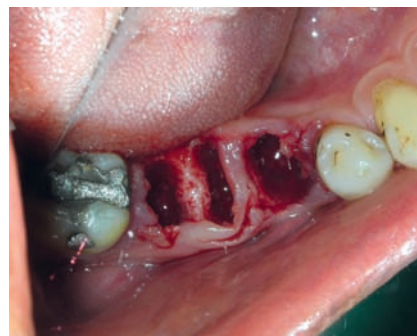Patient	Male, 48 years old
Position	Mandibular right second premolar and first molar, teeth 45 and 46
Initial situation	Fractured teeth that have to be extracted.
Material used	GUIDOR <i>easy-graft</i> CRYSTAL



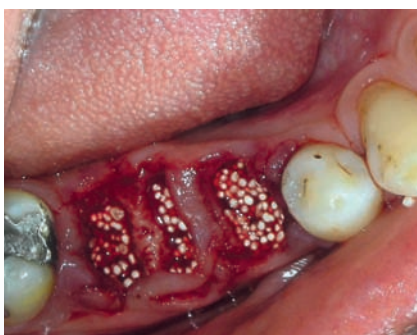**Fig. 1** Pre-op clinical occlusal view with fractured teeth 45 and 46.



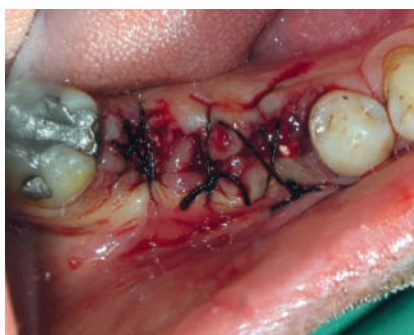**Fig. 2** Preoperative CBCT images of the extraction site showing fractured and unrestorable teeth 45 and 46. Also showing cross section of ridge.



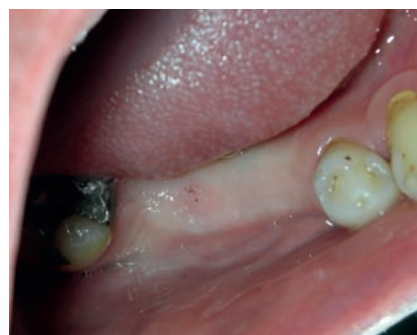**Fig. 3** Post-extraction view of the socket. Note minimal trauma to the soft tissue and no flap reflection on the surgical site.



**Fig. 4** GUIDOR *easy-graft* CRYSTAL condensed into the extraction sockets.

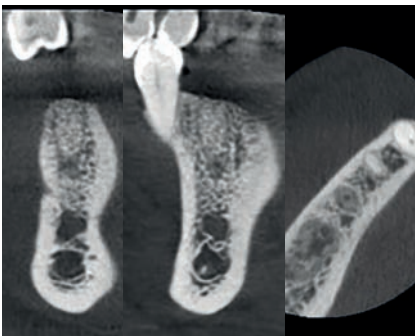


**Fig. 5** Silk sutures with tissue approximation. No releasing incision in the flaps.

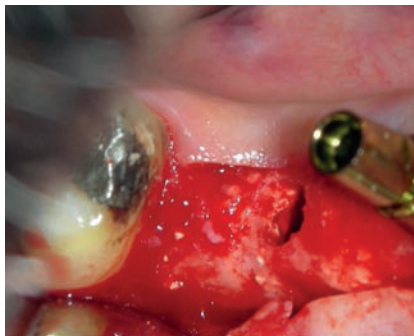


**Fig. 6** Clinical follow-up after 4 months. Note the healing achieved only with tissue approximation. A good width of keratinized tissue is visible along the preserved ridge.

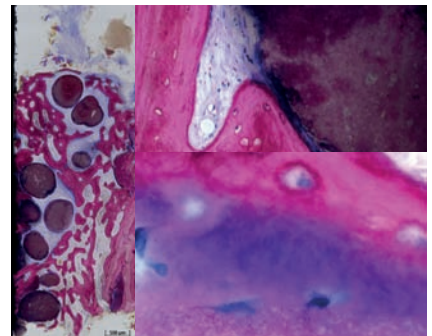
Surgical Approach	Ridge preservation with implant placement at 4 months
Key Steps	<ul style="list-style-type: none"> <li>• Atraumatic tooth extraction and socket cleaning</li> <li>• Ridge preservation with GUIDOR <i>easy-graft</i> CRYSTAL</li> <li>• Silk sutures with tissue approximation</li> <li>• Implant placement at 4 months</li> <li>• Crown placement and loading at 7 months</li> </ul>
Follow-up	7 months



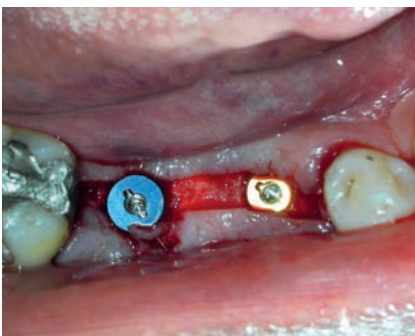**Fig. 7** CBCT at 4 months showing graft integration and preservation of ridge without collapse of the buccal or lingual cortical plates also showing the cross sections in the grafted area.



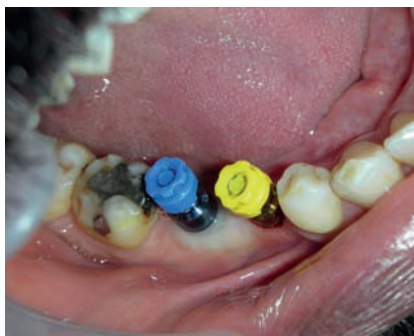**Fig. 8** Implant placed in area 45. Core biopsy sample taken from area 46. Note the integration of graft particles in the preserved alveolar ridge also inside the trephine drill hole at position 46.



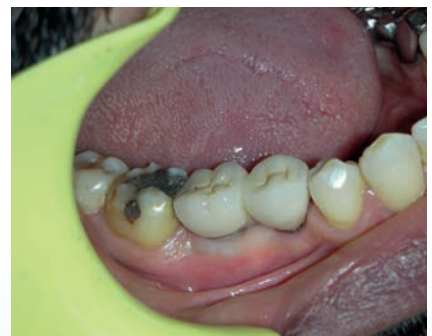**Fig. 9** Histological analysis of bone core biopsy at 4 months: GUIDOR *easy-graft* CRYSTAL particles are in contact with new bone (magenta) or embedded in well perfused connective tissue (blue).



**Fig. 10** Two Xive (Dentsply) implants placed in the preserved ridge.



**Fig. 11** Second stage surgery followed by impression making. Note the excellent width of keratinized tissue.



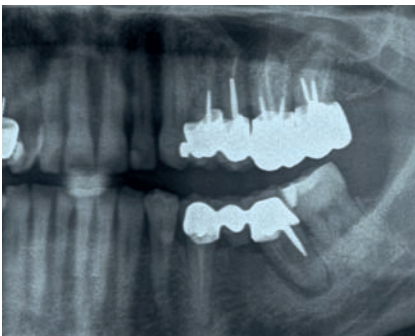
**Fig. 12** Final clinical situation after final restoration at 7 months.

# Ridge Preservation

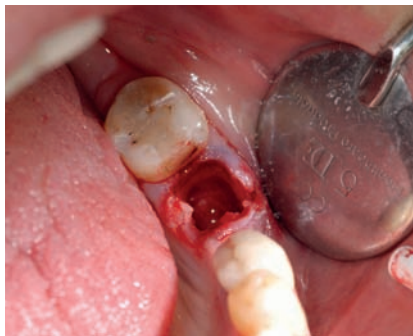## Molar tooth

Dr. Christine Romagna, Beaune, France

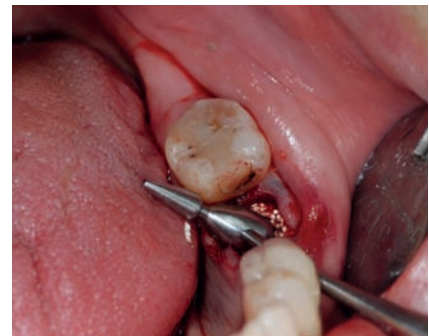Patient	Female
Position	Mandibular left second molar (37)
Initial situation	Hopeless 37 that has to be extracted.
Material used	GUIDOR <i>easy-graft</i> CRYSTAL



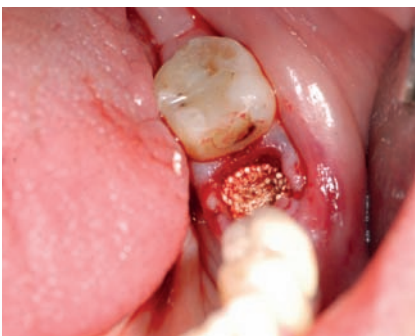**Fig. 1** Initial panoramic x-ray showing the mandibular left second molar that has to be extracted.



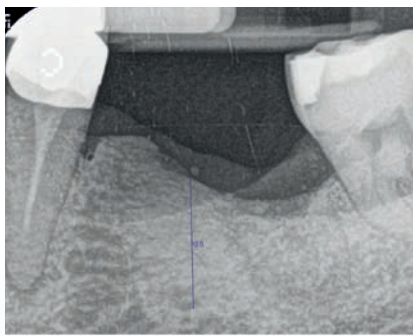
**Fig. 2** Extraction of tooth 37.



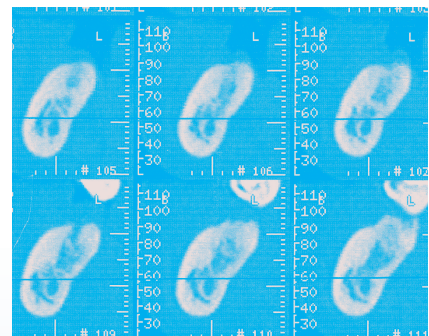
**Fig. 3** Condensation of GUIDOR *easy-graft* CRYSTAL using an amalgam plugger.



**Fig. 4** Situation after grafting with GUIDOR *easy-graft* CRYSTAL.



**Fig. 5** Control x-ray after 8 months.



**Fig. 6** CBCT 10.5 months after operation showing preservation of the ridge dimensions and graft consolidation.

## Surgical Approach

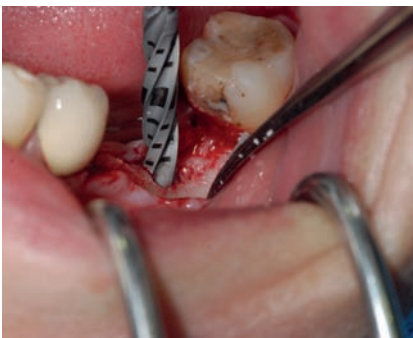Ridge preservation with late implant placement at 14 months

## Key Steps

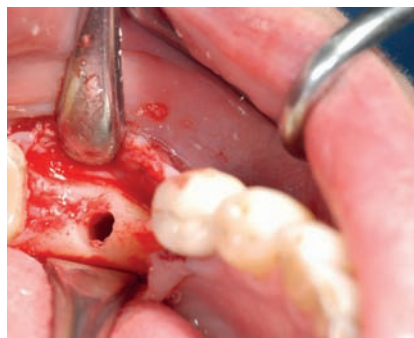- Extraction of tooth 37
- Ridge preservation with GUIDOR *easy-graft* CRYSTAL
- Placement of implant at 14 months

## Follow-up

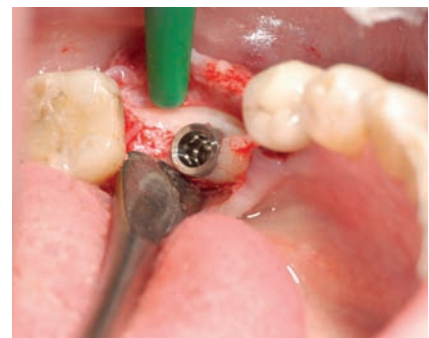4.5 years



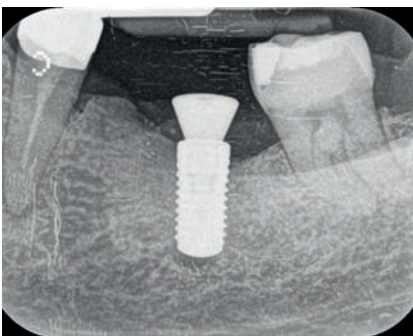
**Fig. 7** Preparation of the implant bed 14 months after ridge preservation.



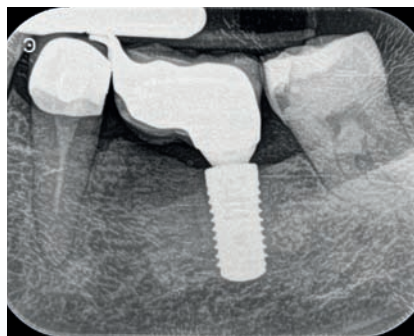**Fig. 8** Occlusal view with open flap before implant placement.



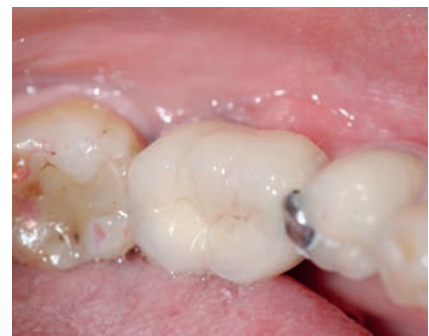**Fig. 9** Implant placement in the preserved ridge (Straumann 4.8 x 10).



**Fig. 10** Control x-ray after implant placement.



**Fig. 11** Control x-ray with final restoration in place, 4.5 years after ridge preservation.



**Fig. 12** Clinical situation with final restoration at 4.5 years.

---

# Disclaimer

Medical science is dynamic and constantly advancing. The presented information is accurate to the best of the authors' knowledge and reflects current knowledge at the time of publication (2018), but we cannot guarantee its correctness and completeness. The document has been written for a professional audience that is able to place the information in the proper context and to assess the risks and advantages of the procedures and methods presented by the authors where they deviate from the traditional schools of thought.

It must be taken into account that indications differ for each patient. Treatment success significantly depends on multiple biological and medical factors as well as on adequate preliminary and follow-up treatment. The authors and the company Sunstar Suisse SA can therefore not guarantee the success of treatment with the suggested treatments.

Any liability for material or immaterial damage arising from the use (or disuse) of this information is excluded. The GUIDOR *easy-graft* CLASSIC, GUIDOR *easy-graft* CRYSTAL, GUIDOR *calc-i-oss* CLASSIC and GUIDOR *calc-i-oss* CRYSTAL instructions-for-use leaflets, which are authoritative regarding therapeutic information, must be observed. Each user is asked to study the instructions for use in detail.

## Links

ITI	International Team for Implantology: .....	<a href="http://www.iti.org">www.iti.org</a>
ICOI	International Congress of Oral Implantologists: .....	<a href="http://www.icoi.org">www.icoi.org</a>
EAO	European Association for Osseointegration: .....	<a href="http://www.eao.org">www.eao.org</a>
EDI	European Association of Dental Implantologists: .....	<a href="http://www.bdizedi.org">www.bdizedi.org</a>

# Cited References

- Araujo M, Linder E and Lindhe J: **Effect of a xenograft on early bone formation in extraction sockets: an experimental study in dog** *Clinical Oral Implants Research* (2009) 20(1): 1-6.
- Araujo M G, Liljenberg B and Lindhe J: **beta-tricalcium phosphate in the early phase of socket healing: an experimental study in the dog** *Clinical Oral Implants Research* (2010) 21(4): 445-54.
- Araujo M G and Lindhe J: **Dimensional ridge alterations following tooth extraction. An experimental study in the dog** *Journal of clinical periodontology* (2005) 32(2): 212-8.
- Avila-Ortiz G, Elangovan S, Kramer K, Blanchette D and Dawson D: **Effect of Alveolar Ridge Preservation after Tooth Extraction A Systematic Review and Meta-analysis** *Journal of Dental Research* (2014) 93(10): 950-958.
- Barone A, Toti P, Marconcini S, Derchi G, Saverio M and Covani U: **Esthetic Outcome of Implants Placed in Fresh Extraction Sockets by Clinicians with or without Experience: A Medium-Term Retrospective Evaluation** *International Journal of Oral & Maxillofacial Implants* (2016) 31(6).
- Beltrán V, Fuentes R and Engelke W: **Endoscopic visualization of anatomic structures as a support tool in oral surgery and implantology** *Journal of Oral and Maxillofacial Surgery* (2012) 70(1): e1-e6.
- Bizenjima T, Takeuchi T, Seshima F and Saito A: **Effect of poly (lactide-co-glycolide) (PLGA)-coated beta-tricalcium phosphate on the healing of rat calvarial bone defects: a comparative study with pure-phase beta-tricalcium phosphate** *Clinical Oral Implants Research* (2016).
- Cardaropoli D, Tamagnone L, Roffredo A and Gaviglio L: **Evaluation of Dental Implants Placed in Preserved and Nonpreserved Postextraction Ridges: A 12-Month Postloading Study** *The International Journal of Periodontics and Restorative Dentistry* (2015) 35(5): 677-85.
- Cordaro L, Bosshardt D D, Palattella P, Rao W, Serino G and Chiapasco M: **Maxillary sinus grafting with Bio-Oss or Straumann Bone Ceramic: histomorphometric results from a randomized controlled multicenter clinical trial** *Clinical Oral Implants Research* (2008) 19(8): 796-803.
- Decco O A, Zuchuat J I, Cura A C, Decco J A and Engelke W: **Conventional extraction vs. enucleation in anterior maxillary sites: a pilot study in humans** *International Journal of Clinical & Experimental Medicine* (2017) 10(2).
- Elia N, Cho S, Froum S, Smith R B and Tarnow D P: **A simplified socket classification and repair technique** *Practical Procedures & Aesthetic Dentistry* (2007) 19(2): 99.
- El Sayed E, Khalil A and Saleh M: **Clinical and radiographical evaluation of immediate implant versus delayed implant after socket preservation of upper anterior teeth** *Alexandria Dental Journal* (2015) 40: 79-85.
- Jurisc M, Manojlovic-Stojanoski M, Andric M, Kokovic V, Danilovic V, Jurisc T and Brkovic B B: **Histological and morphometric aspects of Ridge preservation with a moldable, in situ hardening bone graft substitute** *Archives of Biological Sciences* (2013) 65(2): 429-437.
- Kakar A, Rao B H, Hedge S, Deshpande N, Lindner A, Nagursky H, Patney A and Mahajan H: **Ridge Preservation using an in-situ hardening biphasic Calcium Phosphate (β-TCP/HA) bone graft substitute - A Clinical, Radiological and Histological study.** *International Journal of Implant Dentistry* (2017).
- Leventis M D, Fairbairn P, Kakar A, Leventis A D, Margaritis V, Luckerrath W, Horowitz R A, Rao B H, Lindner A and Nagursky H: **Minimally invasive alveolar ridge preservation utilizing an in situ hardening β-tricalcium phosphate bone substitute. A multicenter case series** *International Journal of Dentistry* (2016) 2016: 5406736.
- Leventis M D and Nagursky H: **Ridge Preservation mit in situ aushärtendem synthetischen Knochenersatzmaterial** *Implantologie Journal* (2014) (4/2014): 46-51.
- Lückerrath W: **Nuovo protocollo chirurgo-protetico minimamente invasivo - Il "Bonner Konzept" [Modern procedure for the creation of an ovate pontic. A new, minimally invasive surgical-prosthetic protocol - The "Bonner Konzept"]** *Il Dentista Moderno* (2017) 2017 (1): 58-63.
- Lückerrath W, Röder L and Enkling N: **The Effect of Primary Stabilization of the Graft in a Combined Surgical and Prosthodontic Ridge Preservation Protocol: A Prospective Controlled Clinical Pilot Study** *International Journal of Periodontics & Restorative Dentistry* (2018) 38(3).
- Lundgren D, Mathisen T and Gottlow J: **The development of a bioresorbable barrier for guided tissue regeneration** *The Journal of the Swedish Dental Association* (1994) 86(13): 741-756.
- Naenni N, Sapata V, Bienz S P, Leventis M, Jung R E, Hämmerle C H and Thoma D S: **Effect of flapless ridge preservation with two different synthetic materials in sockets with buccal dehiscence defects—volumetric and linear changes** *Clinical oral investigations* (2017): 1-11.
- Neldam C A, Sparring J, Rack A, Lauridsen T, Hauge E-M, Jørgensen H L, Jørgensen N R, Feidenhansl R and Pinholt E M: **Synchrotron radiation μCT and histology evaluation of bone-to-implant contact** *Journal of Cranio-Maxillofacial Surgery* (2017).
- Saito H, Shiao H J, Prasad H and Reynolds M A: **Evaluation of a Poly(Lactic-Co-Glycolic) Acid-Coated b-Tricalcium Phosphate Bone Substitute for Alveolar Ridge Preservation: Case Series** *Clinical Advances in Periodontics* (2017) 7(4): 190-194.
- Schmidlin P R, Nicholls F, Kruse A, Zwahlen R A and Weber F E: **Evaluation of moldable, in situ hardening calcium phosphate bone graft substitutes** *Clinical Oral Implants Research* (2013) 24(2): 149-57.
- Schropp L, Wenzel A, Kostopoulos L and Karring T: **Bone healing and soft tissue contour changes following single-tooth extraction: a clinical and radiographic 12-month prospective study** *The International Journal of Periodontics & Restorative Dentistry* (2003) 23(4): 313-23.
- Tan-Chu J H, Tuminelli F J, Kurtz K S and Tarnow D P: **Analysis of buccolingual dimensional changes of the extraction socket using the "ice cream cone" flapless grafting technique.** *The International Journal of Periodontics & Restorative Dentistry* (2014) 34(3): 399-403.
- Tan W L, Wong T L, Wong M C and Lang N P: **A systematic review of post-extraction alveolar hard and soft tissue dimensional changes in humans** *Clinical Oral Implants Research* (2012) 23 Suppl 5: 1-21.
- Valdivia-Gandur I, Engelke W, Beltran V, Borie E, Fuentes R and Manzanares-Céspedes M C: **Novel use of cranial epidural space in rabbits as an animal model to investigate bone volume augmentation potential of different bone graft substitutes** *Head & Face Medicine* (2016) 12(1): 35.
- Van der Weijden F, Dell'Acqua F and Slot D E: **Alveolar bone dimensional changes of post-extraction sockets in humans: a systematic review** *Journal of clinical periodontology* (2009) 36(12): 1048-1058.
- Vignoletti F, Matesanz P, Rodrigo D, Figuero E, Martin C and Sanz M: **Surgical protocols for ridge preservation after tooth extraction. A systematic review** *Clinical Oral Implants Research* (2012) 23 Suppl 5: 22-38.
- Yip I, Ma L, Mattheos N, Dard M and Lang N P: **Defect healing with various bone substitutes** *Clinical Oral Implants Research* (2015) 26(5): 606-14.

# SUNSTAR




GUIDOR *easy-graft*  
GUIDOR *calc-i-oss*

Manufacturer:

Degradable Solutions AG  
Wagistrasse 23  
8952 Schlieren/Zurich  
Switzerland

Distributor:

Sunstar Europe SA  
Route de Pallatex 11  
1163 Etoy  
Switzerland

 0297 Medical Device Class III

Before use, carefully read the instructions for use

For more information, please visit  
[www.guidor.com](http://www.guidor.com) or contact our local affiliate.



GUIDOR, GUM, PAROEX, *easy-graft*, BioLinker and *calc-i-oss* are registered trademarks of Sunstar Suisse S.A. in the USA and in other countries.